

REVIEW ARTICLE

The Prenatal Diagnosis of Genetic Diseases

Peter Wieacker, Johannes Steinhard

SUMMARY

Background: Prenatal diagnosis is a subfield of clinical genetics and gynecology that exemplifies the effective integration of theoretical and clinical medicine. Milestones in its history include the development of cytogenetic, molecular genetic, and molecular cytogenetic methods as well as advances in ultrasonography. The latter technique not only improves the safety of invasive procedures, but also enables earlier and more reliable diagnosis of congenital malformations.

Methods: This article provides an overview of the subject in the light of selectively reviewed literature, guidelines, and recommendations.

Results and conclusion: Invasive prenatal diagnosis is most commonly performed to assess the embryonal/fetal chromosome set. An increasing number of monogenic diseases can be diagnosed prenatally by either genetic or biochemical testing, depending on the particular disease being sought. Polygenic and multifactorial diseases cannot be reliably diagnosed by genetic testing at present, although a number of malformations can be ascertained prenatally by ultrasonography. We discuss the applications and limitations of invasive and noninvasive techniques for prenatal diagnosis.

► Cite this as

Wieacker P, Steinhard J: The prenatal diagnosis of genetic diseases. *Dtsch Arztebl Int* 2010; 107(48): 857–62. DOI: 10.3238/arztebl.2010.0857

Institut für Humangenetik, Universitätsklinikum Münster:
Prof. Dr. med. Wieacker

Klinik und Poliklinik für Frauenheilkunde und Geburtshilfe, Bereich Pränatale Medizin, Universitätsklinikum Münster: Dr. med. Steinhard

The term prenatal diagnosis strictly comprises all diagnostic modalities aimed at gaining information about the embryo or fetus. However in its narrower usage it refers to the prenatal identification of genetically determined diseases and their disposition. In recognition of progress in this area the German Medical Association (Bundesärztekammer, BÄK) published guidelines on prenatal diagnosis of illness and its disposition in 1998 (1).

A disease of wholly or partly genetic in origin is present in around 4% of all neonates. Genetically determined or co-determined diseases can be divided into three groups:

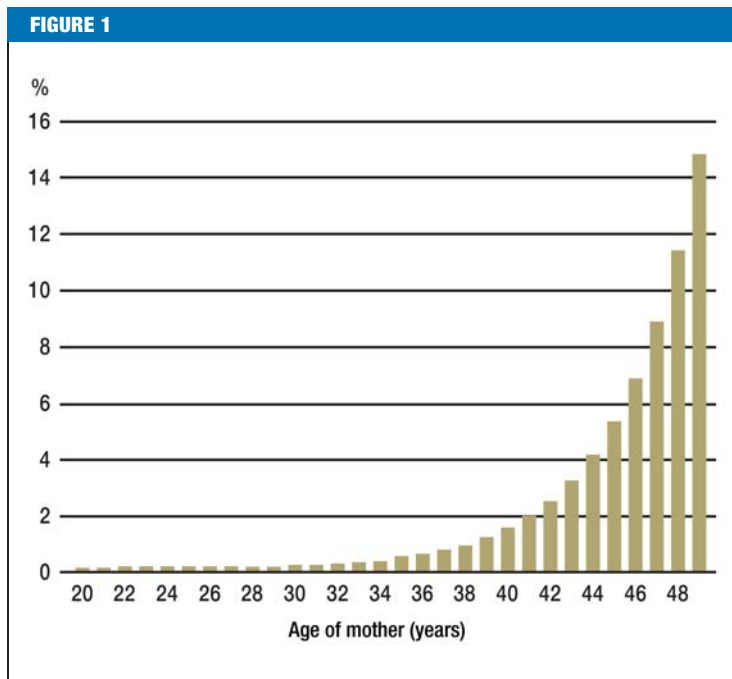
- Chromosomal aberrations
- Monogenic diseases which are caused by single gene mutation
- Polygenic/multifactorial diseases, which are caused by mutations in several genetic areas as well as exogenous factors.

The following article will focus on the applications and limitations of the prenatal diagnosis of chromosomal abnormalities and monogenic diseases, but will not focus on ultrasonographic diagnosis of fetal anomalies, whether occurring in isolation or as part of syndromes including monogenetically inherited diseases.

The prenatal diagnosis of chromosomal abnormalities

Common reasons for karyotype analysis are:

- Maternal age: the probability of chromosomal anomalies increases with maternal age (*Figure 1*). Around half of chromosomal anomalies are accounted for by trisomy 21 (Down syndrome) (2)
- Following an abnormal result from non-invasive screening
- Following an ultrasound finding which raises the possibility of a chromosomal problem
- In the presence of a known translocation, inversion or insertion in one parent; in these cases, the probability of an unbalanced aberration is increased, over and above the maternal age-related risk.
- A chromosomal anomaly in an existing child of the couple's. For example, after the birth of a child with free trisomy, the risk of a numerical chromosomal abnormality is increased by 1% for



Probability of a chromosomal abnormality in the neonate dependent on maternal age (from Hooke, 1981) (2)

each subsequent child compared to other parents of the same age (3).

As chromosome analysis requires cellular material, an appropriate intervention is needed, of which several are available, depending on gestation, clinical question, and interventional risk (Table 1, eBox 1).

Amniocentesis

Amniocentesis is typically carried out under ultrasonographic control, between 15 and 17 weeks of pregnancy. The procedure specific risk is 0.5% to 1% (3). Around 15 mL of amniotic fluid would normally be aspirated. Chromosomal analysis requires prior cell culture, which takes on average two weeks. After this metaphase chromosomes are analyzed numerically and structurally (Figure 2). Uncultured amniotic fluid can be used to determine levels of alpha fetoprotein (AFP), which is present in increased concentrations in open neural tube defects and other disorders such as abdominal wall defects (e.g., gastroschisis). In the presence of a raised AFP level, acetylcholinesterase is measured as a marker of neural tube defects (eBox 2).

Amniocentesis can also be used in conjunction with a rapid screening test for numerical aberrations of specific chromosomes, which can be used on uncultured amniotic fluid, in conjunction with conventional cytogenetic analysis. Using FISH analysis (fluorescent in situ hybridization) with chromosome-specific probes at interphase nuclei or via molecular genetic analysis of highly polymorphic markers on a DNA probe isolated from uncultured amniotic fluid cells, information can

be obtained regarding numerical abnormalities of chromosomes 13, 18 and 21, and the X and Y chromosomes (Figure 3). This test allows detection of the commonest chromosomal anomalies within one to three days. This test is of particular importance where morphological abnormalities potentially associated with the above conditions have been detected, and where a rapid diagnosis is required at a late stage of pregnancy. A prenatal rapid test can serve to reassure the pregnant woman if normal, but cannot replace formal karyotyping (<http://www.gfhev.de/en/documents/index.htm>).

Chorionic villus sampling

Chorionic villus sampling (CVS) is typically performed in the 11th to 12th weeks of pregnancy. It should not be carried out before the 11th week in view of the increased risk of limb abnormalities associated with CVS prior to this date, which some commentators have linked to placental trauma and vascular infarction at a critical stage of development. Depending on placental site, CVS can be carried out either transcervically or transabdominally. Chromosome analysis is carried out either as a direct preparation or following brief culture (1 day) as well as after full culture (7 to 10 days). In experienced hands the procedure-specific risk of miscarriage is up to 1% (eBox 3).

Placental biopsy

Placental biopsy is in effect late transabdominal chorionic villus sampling. It can be used to obtain a rapid result at a late stage of pregnancy.

Cordocentesis

Cordocentesis is a technically challenging intervention in which the umbilical vein is entered where possible at the site of placental insertion. The commonest indications are suspected fetal anemia in association with rhesus disease, parvovirus B19 infection, or fetal hydrops. Cordocentesis can also be used for rapid karyotyping or molecular genetic diagnosis from 16 to 20 weeks, depending on indication. Cordocentesis is important where a rapid result is needed late in pregnancy, for example in the presence of ultrasonographically detected anomalies or severe growth restriction, which may point to a chromosomal abnormality. The result of chromosome analysis of lymphocytes from cord blood can be available in three to five days.

The limitations of cytogenetic diagnosis

Prenatal karyotyping is a reliable procedure, but like all tests, limited by factors which can be technical or biological. The probability of obtaining no fetal cellular material is less than 1% in experienced hands. Culture failure can occasionally occur.

One limitation of cytogenetic diagnosis arises via the optical resolution of the chromosomes. Structural chromosomal abnormalities smaller than the achievable optical resolution cannot be detected. A further limitation relates to the detection of a possible chromosomal

mosaic, where two or more cell lines can be present. A mosaic can only be detected if chromosomally aberrant cells are present in the examined specimen.

The demonstration of certain structural abnormalities such as translocation or inversion often requires further investigation (*eBox 4*).

Noninvasive investigations

Invasive prenatal diagnosis on the grounds of maternal age is increasingly being replaced by combined assessment of risk factors, of which maternal age is just one. The miscarriage risk in particular drives a need for non-invasive alternatives to the above interventions. In addition to maternal age, certain biochemical parameters in maternal blood and first trimester ultrasonographic appearances allow individualized assessment of the risk of aneuploidy. Counselling should make it clear that these noninvasive methods modify the maternal age-related risk of certain chromosomal abnormalities, but cannot rule out chromosomal abnormality. They can however aid decision making for or against an invasive method.

Nuchal translucency screening

Increased nuchal translucency in the fetus is associated with increased risk of chromosomal abnormality and other diseases (4). Sonographic measurement of the thickness of the nuchal fold between 11+0 and 13+6 weeks of pregnancy, together with maternal age and biochemical markers allows an individualized risk of aneuploidies such as trisomy 21, 13, and 18 to be calculated. This allows, for a screen-positive rate of 5 %, 80 % (nuchal translucency only) to 90% (nuchal translucency plus biochemical parameters) of cases of trisomy 21 to be detected (*Table 2*). However, nuchal translucency measurement is not comparable with targeted anomaly diagnosis carried out in a specialist setting as part of a so-called extended first trimester screening. The aim of this type of early anomaly scan is to identify fetal anomalies, with nuchal thickness as an integrated part. The German Society for Ultrasound in Medicine (*Deutsche Gesellschaft für Ultraschall in der Medizin, DEGUM*) (5) advises gynecologists in possession of a nuchal translucency measurement certificate but who do not have a specialist qualification in anomaly scanning to refer women with abnormal nuchal thickness measurements (greater than the 95th centile for gestational age) and multiple pregnancy to a specialist center (DEGUM level II or III). This patient group may conceal numerous additional diseases such as cardiac anomalies, in addition to chromosomal anomalies (4).

Prerequisites for an interpretable nuchal thickness measurement include operator qualification, choice of appropriate duration of investigation, and technical considerations. Inclusion of additional parameters such as measurement of the nasal bone, Doppler assessment of the tricuspid valve, and the ductus venosus, and the facial angle allows individualised detection rates for trisomy 21 to be increased to up to 95% (*Table 2*).

TABLE 1

Invasive prenatal diagnostic methods

Technique	Timing	Miscarriage risk	Applications
Chorionic villus sampling	11–14 weeks	~ 1 %	– chromosome analysis (karyotyping) – molecular genetic diagnosis – biochemical diagnosis
Amniocentesis	15–17 weeks	0.5 %–1 %	– chromosome analysis – diagnosis of open neural tube defects – molecular genetic diagnosis – biochemical diagnosis
Placental biopsy	From 15 weeks	~ 1 %	– chromosome analysis – molecular genetic diagnosis – biochemical diagnosis
Cordocentesis	from 16–20 weeks * ¹	~ 1 %	– chromosome analysis – hematological and biochemical diagnosis
Fetal biopsy	from 20 weeks	* ²	– diagnosis of specific genetic dermatoses

*¹ by indication
*² The miscarriage risk must be quoted by the institution offering invasive testing

Biochemical parameters

In recent years, the measurement of human chorionic gonadotrophin (HCG) and pregnancy-associated plasma protein A (PAPP-A) in maternal serum between the 11th and 14th weeks of pregnancy have become increasingly established in combination with nuchal translucency measurement and maternal age (combined first trimester test). (5). Prior to this, the so-called triple test was offered (6), measuring alpha fetoprotein (AFP), HCG and free estriol between 15 and 20 weeks. A further biochemical parameter, Inhibin A, when added to the triple test, yields the so-called quadruple test (7). Accurate assessment of gestational age is essential for interpreting the biochemical parameters. As PAPP-A and HCG measurement in association with nuchal translucency measurement are always carried out in conjunction with fetal biometry, for example using the crown rump length, this allows concurrent assessment of gestational age. This is not the case with the triple test. Laboratories calculate individual risks for trisomy 21, 13 and 18 and for neural tube defects using the gestation as reported by the gynecologist. This often involves using the last menstrual period, which leads to a relatively high level of error. In our experience, couples are often worried unnecessarily by a wrongly calculated triple test. This, together with the possibility of earlier and more precise risk assessment in the first trimester, is an argument against the triple test.

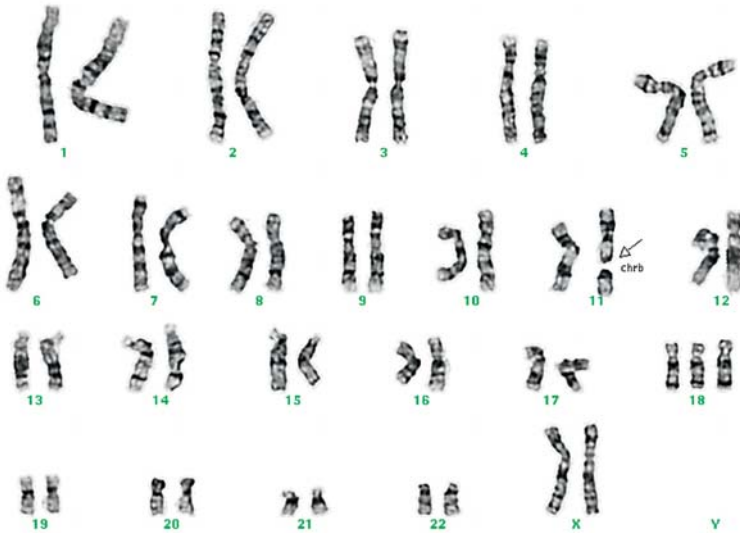


Figure 2: Karyotype of a fetus with trisomy 18. Three copies of chromosome 18 can be seen. One copy of chromosome 11 shows a break (see arrow) consistent with a preparation artefact

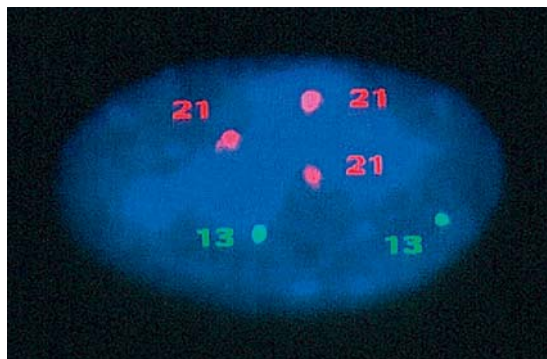


Figure 3: Demonstration of Down syndrome (trisomy 21) in a prenatal rapid diagnostic test using FISH analysis with probes specific for chromosomes 13 (green) and 21 (red). The three red signals confirm trisomy 21

Prenatal diagnosis of monogenetically determined diseases

At the present time around 5000 known disorders are inherited in a monogenetic mendelian fashion. Foremost among them are autosomal dominant, autosomal recessive and X-linked disorders, which carry a higher risk of illness than that conveyed by age-related risk. An autosomal dominant condition carries an a priori 50% inheritance risk where one parent is affected. An autosomal recessive disease carries a 25% inheritance risk for children of a healthy carrier couple. An X-linked recessive disorder carries a 50% risk for the son of a carrier mother.

Specific, albeit non-screening genetic tests are currently available for more than 1000 of these diseases.

Unlike cytogenetic prenatal diagnosis based on maternal age, prenatal gene testing is not a screening test. Given the individuality of each case, prior planning is essential. Two differing strategies are possible: indirect and direct genetic testing.

Direct genetic testing involves the identification or exclusion of the relevant mutation(s), and assumes knowledge of existing mutations in the index patient.

Indirect genetic testing involves the demonstration or exclusion of the so-called high risk haplotype in the fetus. Indirect genetic testing uses the principle of genetic linkage, and requires examination of the family for polymorphic markers whose alleles are closely associated with disease in this family. In theory, all that is required in an informative family is the locus of the relevant gene. Diagnostic uncertainty arises where there is heterogeneity in the gene locus, i.e. when mutations in different genes lead to the same disease. An additional, albeit quantifiable uncertainty arises where a gene recombines with a linked marker. It is obvious that the reliable interpretation of indirect genetic testing presupposes that the stated relationships within the pedigree are correct.

In a positive prenatal diagnostic test, especially for an autosomal dominant condition, the possibility of variable expression and reduced penetrance must be borne in mind. Variable expressivity of a mutation occurs when the resulting phenotype is more or less strongly expressed in different members of the same family.

Reduced penetrance implies missing expression of the mutation. In this situation the phenotype can be normal despite the mutation. Variable expression and reduced penetrance can be explained by as yet largely unknown modifying factors. For this reason it is important to discuss these issues during genetic counselling.

For reasons dictated by time and technical considerations, a molecular genetic test is usually carried out in the context of CVS following polymerase chain reaction (PCR) for amplification of DNA isolated from chorionic villi, before eventual DNA sequencing can be carried out (*eBox 5*).

Inherited metabolic disorders can in some cases be diagnosed from chorionic villi or amniotic cells (10). The prerequisite for this is that the relevant gene is expressed in these cells and the metabolic defect has been detected in fibroblasts (via skin biopsy) in an index patient within the family. Some genetic disorders are sought directly in the amniotic fluid (*eBox 6*).

Genetic counselling in prenatal diagnosis

The German genetic testing act (Gendiagnostikgesetz) of February 1, 2010 stipulates that pregnant women must be offered genetic counselling before and after prenatal diagnostic testing (11). The following areas should be covered:

- Presentation of the background risk of congenital disease and anomaly, and individual increased risks (for example increased maternal age)

- The options and limitations for prenatal genetic diagnosis
- Possible diseases which can be detected
- Risks associated with the relevant tests
- Conflictual areas in relation to prenatal diagnosis
- Alternatives.

Even the possibility of prenatal diagnosis can plunge a couple into conflictual areas. In many cases prenatal diagnosis can provide reassurance. However, only in a small number of cases can pathology be effectively treated by early intrauterine or neonatal treatment. The detection of significant disease or impairment can be grounds for termination of pregnancy. According to article 218 a paragraph 2 StGB (Strafgesetzbuch, the German Criminal Law), termination of pregnancy by a medical practitioner with the consent of the pregnant woman is legal when: „... after consideration of the present and future terms of living of the pregnant woman it is medically established that, in order to prevent danger to the life or danger of severe impairment of the physical or mental health of the mother, and this danger cannot be prevented by any other means acceptable to her“. In this conflict between the parents' wish for a healthy child and the basic recognition of protection for the unborn child, termination of pregnancy following the detection of severe fetal illness or impairment represents „an incomplete attempt to end a fundamentally insoluble conflict“ (1).

The principle of non-directiveness must be applied in all genetic counselling including prenatal diagnosis. In this context it should be made clear that a **pathological result in no way automatically implies termination of pregnancy**. In addition to genetic counselling as part of prenatal diagnosis, **psychosocial counselling can be offered**. This may help the couple face and resolve the conflicts discussed, via exploration of the possible consequences of diagnosis, and offer support in dealing with serious fetal anomaly. **This is particularly advisable in the case of serious anomaly**. The new pregnancy conflict act which took force on January 1, 2010 stipulates that women considering legal termination of pregnancy must receive advice about psychosocial implications. **Likewise, the woman must be informed of her right to appropriate psychosocial counselling and other specialist medical advice such as that of a specialized pediatrician**. The responsibility for communication of this information lies with the doctor who confirms the indication for termination of pregnancy. In addition, a three day “cooling off period” is required following communication of a diagnosis before the formal indication for termination of pregnancy can be confirmed (eBox 7).

Acknowledgement

We wish to thank Prof. P. Propping (Bonn) for critical discussion.

Conflict of interest statement

The authors declare no conflict of interest in the terms of the guidelines of the International Committee of Medical Journal Editors.

Manuscript submitted on 17 November 2009, revised version accepted on 11 February 2010.

TABLE 2

Detection rates for trisomy 21 plotted against the type of screening parameters and tests used (modified from [8] and [9])

1st trimester (11–14 weeks)	
Maternal age	30–50%
PAPP-A, HCG, MA	60–63%
NT measurement and MA	74–80%
Combined test (NT, PAPP-A, HCG, MA)	86–90%
Combined test plus nasal bone, tricuspid flow, ductus venosus and facial angle	95%
2nd trimester (15–19 weeks)	
Maternal age	30–50%
2nd trimester double test (AFP, HCG, MA)	60%
Triple test (AFP, HCG, E3, MA)	68%
Quadruple test (AFP, HCG, E3, Inhibin A, MA)	79%
Ultrasound (16–23 weeks) with anomaly screening	75%
Invasive diagnostic testing	
Chorionic villus sampling	close to 100%
Amniocentesis	close to 100%

Modified from Bethune 2007 (8) and Nicolaides 2008 (9); MA, maternal age; PAPP-A, pregnancy associated plasma protein A; HCG, human chorionic gonadotropin; NT, nuchal translucency; AFP, alpha 1 fetoprotein; E3, estriol

REFERENCES

1. Bekanntgaben der Herausgeber: Bundesärztekammer: Richtlinien zur pränatalen Diagnostik von Krankheiten und Krankheitsdispositionen. Dtsch Arztebl 1998; 95(50): A 3238–44.
2. Hooke E: Rates of chromosome abnormalities at different maternal ages. Obstet Gynecol 1981; 58: 282–5.
3. Murken J: Pränatale Diagnostik. In: Murken J, Grimm T, Holinski-Feder E (eds.): Humangenetik. 7th edition. Stuttgart: Thieme Verlag 2006; 386–411.
4. Wald NJ, Morris JK, Walker K, Simpson JM: Prenatal screening for serious congenital heart defects using translucency: a meta-analysis. Pren Diagn 2008; 28: 1094–104.
5. Nicolaides KH, Azar G, Byrne D, Mansur C, Marks K: Fetal nuchal translucency: ultrasound screening for chromosomal defects in first trimester of pregnancy. BMJ 1992; 304: 867–89.
6. Wald NJ, Cuckle HS, Denslem JW, et al.: Maternal serum screening for Down's syndrome in early pregnancy. BMJ 1988; 297: 883–7.
7. Wald NJ, Denslem JW, George L, Muttukrishna S, Knight PG: Prenatal screening for Down's syndrome using inhibin-A as a serum marker. Prenat Diagn 1996; 16: 143–52.
8. Bethune M: Literature review and suggested protocol for managing ultrasound soft markers for Down syndrome: thickened nuchal fold, echogenic bowel, shortened femur, shortened humerus, pyelectasis and absent or hypoplastic nasal bone. Austr Radiol 2007; 51: 218–25.
9. Nicolaides K: Some thoughts on the true value of ultrasound. Ultrasound Obstet Gynecol 2007; 30: 671–4.
10. The Online Metabolic and Molecular Bases of inherited diseases (<http://www.ommbid.com/>)

11. Gesetz über genetische Untersuchungen bei Menschen (Gendiagnostikgesetz – GenDG), Bundesgesetzblatt 2009; Nr. 50.

Corresponding author

Prof. Dr. med. Peter Wieacker
 Institut für Humangenetik, Vesaliusweg 12–14,
 48149 Münster, Germany
 wieacker@uni-muenster.de



For eReferences please refer to:
www.aerzteblatt-international.de/ref4810

eFigure and eBoxes available at:
www.aerzteblatt-international.de/10m0857

KEY MESSAGES

- The risk of chromosomal abnormality in the fetus increases with increasing maternal age. Trisomy 21 accounts for around half of cases.
- Invasive diagnosis of chromosomal abnormalities can be carried out using a variety of techniques, such as chorionic villus sampling and amniocentesis.
- Sonographic measurement of nuchal lucency between 11+0 and 13+6 weeks of pregnancy combined with maternal age and biochemical parameters allows individualized risk calculation for some aneuploidies such as trisomy 21, 13 und 18.
- In the presence of ultrasound abnormalities in the 1st trimester and a high risk 1st trimester screening result, chorionic villus sampling should be offered as the most rapid invasive diagnostic method.
- Monogenetically inherited diseases can to some extent be diagnosed prenatally via molecular genetic tests.
- Prior to prenatal diagnostic testing with the aim of detecting genetic disease, genetic counselling must be carried out, in accordance with the German Genetic Diagnosis Act which came into force on February 1, 2010. This must be non-directive, as must any genetic counselling.

REVIEW ARTICLE

The Prenatal Diagnosis of Genetic Diseases

Peter Wieacker, Johannes Steinhard

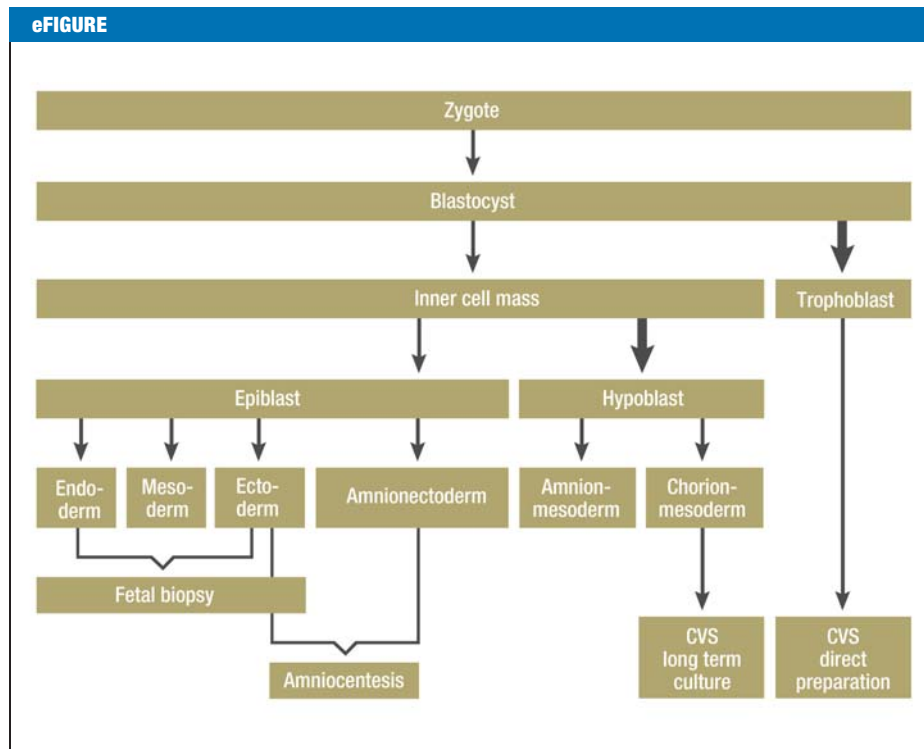
eReferences

- e1. Jackson LG, Zachary JM, Fowler SE, et al.: A randomized comparison of transcervical and transabdominal chorionic-villous sampling. The U.S. National Institute of Child Health and Human Development Chorionic-Villous Sampling and Amniocentesis Study Group. *N Engl J Med* 1992; 327: 594–8.
- e2. Multicentre randomised clinical trial of chorion villus sampling and amniocentesis. First report. Canadian Collaborative CVS-Amniocentesis Clinical Trial Group. *Lancet* 1989; 1(8628): 1–6.
- e3. Rhoads GG, Jackson LG, Schlesselman SE, et al.: The safety and efficacy of chorionic villus sampling for early prenatal diagnosis of cytogenetic abnormalities. *N Engl J Med* 1989; 320: 609–17.
- e4. Medical Research Council European trial of chorion villus sampling. MRC working party on the evaluation of chorion villus sampling. *Lancet* 1991; 337: 1491–9.
- e5. Caughey AB, Hopkins LM, Norton ME: Chorionic villus sampling compared with amniocentesis and the difference in the rate of pregnancy loss. *Obstet Gynecol* 2006; 108: 612–6.
- e6. Merz E, Meinel K, Bals R, et al.: DEGUM-Stufe-III-Empfehlung zur „weiterführenden“ sonografischen Untersuchung (= DEGUM Stufe II) im Zeitraum 11–14 Schwangerschaftswochen. *Ultraschall in Med* 2004; 25: 218–20.
- e7. Nicolaides KH, von Kaisenberg CS: Die Ultraschalluntersuchung von 11–13+6 Schwangerschaftswochen. London: Fetal Medicine Foundation 2004; www.fetalmedicine.com
- e8. Gardner RJ, Sutherland GR: Chromosome abnormalities and genetic counseling. Oxford: University Press 2004.
- e9. Warburton D: De novo balanced chromosome rearrangements and extra chromosomes identified at prenatal diagnosis: Clinical significance and distribution of breakpoints. *Am J Hum Genet* 1991; 49: 995–1013.
- e10. Buchholz T, Vogt U, Clement-Sengewald: Polkörperdiagnostik in Deutschland – Erfahrungen und neue Entwicklungen. *J Reproduktionsmed Endokrinol* 2006; 4: 215–8.
- e11. Aymé S, Nippert I, Marteau T and the EUROCAT working group: Variations between European regions in termination rates for fetal abnormalities: why is it so? *Medgen* 1999; 11: 126.
- e12. DADA Study Group comprising Marteau T, Nippert I, et al.: Outcomes of pregnancies diagnosed with Klinefelter syndrome: the possible influence of health professionals. *Prenat Diagn* 2002; 22: 562–6.

REVIEW ARTICLE

The Prenatal Diagnosis of Genetic Diseases

Peter Wieacker, Johannes Steinhard



The embryological development of tissues which can be used for prenatal diagnosis (modified from [10]); around a quarter of blastocyst cells form the inner cell mass. CVS, chorionic villus sampling

REVIEW ARTICLE

The Prenatal Diagnosis of Genetic Diseases

Peter Wieacker, Johannes Steinhard

eBOX 1**Source of cells used for prenatal diagnostic tests**

Cells of differing sources are used, depending on the intervention. This is important in interpreting the prognosis for possible mosaics. Around three quarters of blastocyst cells develop into trophoblast cells, which form the outer layer of the chorionic villi. Around a quarter become the inner cell mass, which differentiates into hypoblast and epiblast. The chorion and amnion mesoderm develop from the hypoblast, while the epiblast gives rise to the three germ layers (ectoderm, mesoderm and endoderm) and the amnion ectoderm (*eFigure*).

eBOX 2**The cytogenetic analysis of amnion cells**

Cytogenetic analysis uses a culture of amnion cells enriched in the sediment following centrifugation. The amnion cells are derived from the fetal ectoderm (in particular from the skin and lower urinary tract). Using the culture flask method, at least two cultures are grown in order to reduce the risk of failure and improve interpretation of chromosomal mosaics. At least 15 metaphases are analyzed numerically and at least 5 structurally. With the in-situ method, at least 15 metaphases from 6 clones are analyzed. A band resolution of at least 400 bands in relation to the haploid chromosome set is required for chromosome analysis (from ICSN) (Guideline on Cytogenetic Laboratory Diagnosis: www.gfhev.de).

eBOX 3

The cytogenetic analysis of chorionic villi and the risk of miscarriage in chorionic villus sampling

The cytogenetic analysis of chorionic villi requires analysis both after direct preparation (1 day) as after long term culture (7–10 days) because in this way cells of differing embryonal origin can be examined. The minimum requirement for chromosome analysis of chorionic villi is a resolution of 300 bands (in relation to the haploid chromosome set).

The reported miscarriage risk following chorionic villus sampling varies by study. A large scale randomized trial (e1) of 3999 pregnancies found no difference in miscarriage rate between transcervical and transabdominal chorionic villus sampling (CVS). A Canadian multicenter study of 2787 women (e2) and a large American study (e3) both showed no significant difference in miscarriage rate between CVS and amniocentesis. However, a European multicentre study found a higher rate of complication for CVS than for amniocentesis (e4). A recently published single centre study (e5) compared 5 243 chorionic villus biopsies with 4 917 cases where no invasive testing was carried out, and found no difference in miscarriage risk. Overall, the data suggest that operator experience and training are central to the complication rate. With appropriate experience the miscarriage rate should be in the region of up to 1%.

The German Society for Ultrasound in Medicine (Deutsche Gesellschaft für Ultraschall in der Medizin, DEGUM) and the London based Fetal Medicine Foundation (FMF) recommend that CVS should be offered as the most rapid invasive diagnostic test to women in whom an ultrasound abnormality or an increased risk of chromosomal abnormality at first trimester screening have been found (e6, e7). It is not acceptable for a woman who has chosen invasive testing in the face of an increased risk to have to wait weeks for amniocentesis. At the very least she should be offered the alternative option of early karyotyping.

eBOX 4

Diagnostic problems in cytogenetic prenatal diagnosis

Conventional chromosome analysis is unable to detect structural changes below the limits of the achievable optical resolution. More recently a new method, Array-CGH (Comparative Genomic Hybridization) has been developed to overcome this barrier. This entails competitive hybridisation of reference DNA and patient DNA which are marked, respectively with different coloured fluorescent markers (red and green) in a micro array. A genomic array of this type allows defined genome fragments to be fixed in a matrix-like formation, for example on a glass slide. Co-hybridization of reference and test DNA allows the detection of losses and gains such as deletions or duplications, via the red-green ratio. This allows the detection of microdeletions and microduplications which cannot be detected by conventional chromosomal analysis. However, changes with pathological implications must be distinguished from copy number variants of no clinical significance. It is to be anticipated that this technology will form an important part of prenatal diagnosis in future, if appropriate microarrays for the relevant clinical questions are validated in advance.

The observation of individual or small numbers of cells with a chromosomal aberration can present a diagnostic problem. A distinction is made between "true mosaics," in whom aberrant cells are present in the fetus or the placenta alone (confined placental mosaicism), and pseudomosaics, in whom the aberrant cells have arisen during culture or as a preparation artefact. An international classification has become established for interpreting findings such as these, and offering guidance on how to proceed, taking the affected chromosome into account (e8). For example, in some cases, cordocentesis can be undertaken to obtain further clarification of uncertain mosaics following chorionic villus sampling (CVS) or amniocentesis.

Another diagnostic challenge can arise when a translocation or inversion is found. In this case it is important first to determine whether the chromosomal anomaly arises from one of the parents, or has arisen de novo. In the case of its being inherited, the likelihood of a detectable increased risk of congenital abnormality is small. Where an anomaly, such as a translocation or inversion, has arisen de novo, the possibility of genetic damage arising from a break in a gene cannot be ruled out. Empirically derived risk estimates are available to aid assessment of this risk. The probability of congenital disease or anomaly is around 6% following a de novo reciprocal translocation and around 9.4% following a de novo inversion. It is also possible that cytogenetic prenatal diagnosis may reveal a marker chromosome. A marker chromosome is a structurally altered chromosome whose composition cannot be determined using conventional banding techniques. A newly arisen marker chromosome is associated with a probability of congenital disease or anomaly of on average 15% (e9). Special Fluorescent in-situ hybridization techniques (FISH) may modify this probability. In any case detailed anomaly scanning should be carried out in a specialist center with a view to detecting possible abnormalities. The limits of ultrasound to detect abnormalities should be borne in mind.

eBOX 5

Contamination of chorionic villi with maternal cells as a source of error in the prenatal diagnosis of monogenetically inherited defects

If chorionic villi are contaminated with maternal cells the possibility of misdiagnosis arises. For this reason this type of diagnostic procedure should always be accompanied by a contamination check. This involves the characterization of alleles using short tandem repeats in maternal DNA and DNA from the chorionic biopsy specimen. If the chorionic biopsy specimen contains two maternal alleles for a single locus, contamination with maternal cells is obvious. This is an indication for a repeat procedure.

eBOX 6

Preimplantation diagnosis

In contrast to prenatal diagnosis, preimplantation diagnosis (PID) is carried out on embryonic cells prior to the establishment of pregnancy. This requires in vitro fertilization (IVF) or intracytoplasmic sperm injection (ICSI). After cultivation of the embryo to the 8 cell stage, one cell (blastomere), typically, is removed for molecular cytogenetic or molecular genetic analysis

The applications of PID are:

- The detection or exclusion of a specific unbalanced chromosome translocation, where one parent carries a Robertsonian or reciprocal translocation.
- The detection or exclusion of a particular mutation in the presence of an increased risk of a monogenetically inherited disease.

As PID is not carried out in Germany due to the German Embryo Protection Act, the risks and benefits of this method are not discussed in this article. The legal status of PID is currently under new discussion in Germany following a recent court judgment.

Polar body diagnosis is a method of preconceptual examination of the oocyte which offers a possible alternative to PID. This requires IVF or ICSI. The first polar body arises after the first meiotic division, and contains a haploid genotype of normally 23 chromosomes, with each chromosome comprising two chromatids. The second polar body arises following the second meiotic division, with each chromosome comprising a single chromatid. The first polar body develops shortly before ovulation. The second polar body is available 5 to 6 hours after penetration of the oocytes by the sperm, and therefore following ICSI, for example. In order to comply with the requirements of the German Embryo Protection Act, polar body diagnosis must be complete by 20 hours following ICSI, as by this stage the female and male pronuclei have fused and an embryo has been created.

Polar body diagnosis can be used when the woman carries a balanced translocation or the predisposition to a monogenetically inherited disease. Polar body diagnosis is currently offered only in a few centers in Germany (e10). Prior to IVF / ICSI, it must be decided for each case whether polar body diagnosis is feasible. In reproductive medicine, it is hoped that polar body diagnosis will lead to increased success rates for ICSI, by exclusion of chromosomally aberrant oocytes from fertilization.

eBOX 7

Clinical decision making following prenatal diagnosis

European studies of the basis on which couples decide to proceed despite a pathological finding on prenatal diagnosis show that this varies not only according to the type of disease detected, but by region and counselling approach. For example, following prenatal diagnosis of Down syndrome around 67% of couple in the Italian region of Catania choose termination of pregnancy, compared with around 95% in other European regions (e11). The rate of termination of pregnancy in Klinefelter syndrome was on average 44% (from 0 to 76% depending on center) (e12).